

Canine Analysis report

Oscar's Tale



Owner Name
Andrina Haerles

Test Report Code
LHK220923002

Date Printed,
28, October, 2022



Content

1.OVERVIEW

2.DETAILS

2.1 Breed

2.2 Genetic diseases

2.3 Hair trait

2.4 Behaviors

3.REFERENCES





1 Overview

Overview

Oscar's samples were submitted for a full set of genetic testing for dogs, including breed identification, single-gene genetic disease detection, complex disease detection, hair trait and behaviour determination. The analysis of sample received for PETGEN74429UK was completed and reported on 28, October, 2022.

Sample quality

DNA extraction was successful. The specific information is as follows:

Sample ID	Total Reads	Reads matched with primer	Effective average depth	Ontarget ratio	Q20
LHK220923002	1424032	1287609	812.3716	0.9042	0.9718

Breed identification

In this test, the sample is a mixed breed of Puli, Pomeranian, Labrador Retriever, Chow Chow.



Puli



Pomeranian



Labrador Retriever



Chow Chow

Disease detection

133 canine single-gene genetic diseases was tested. 0 single gene mutation was detected in this sample.

Single-gene genetic diseases	Risk
None	None

Detected Complex genetic diseases are as follows:

Complex genetic diseases	Relative risk(%)
Congenital sensorineural deafness	89.99
Obsessive-compulsive disorder	87.76
Congenital megaesophagus	65.64
Mast cell tumor(MCT)	64.32
Hemangiosarcoma	31.1
Lymphoma	30.92
Portosystemic vascular anomaly(PSVA)	28.21
Hypothyroidism	26.58
Hip dysplasia	9.16
Osteosarcoma	8.98

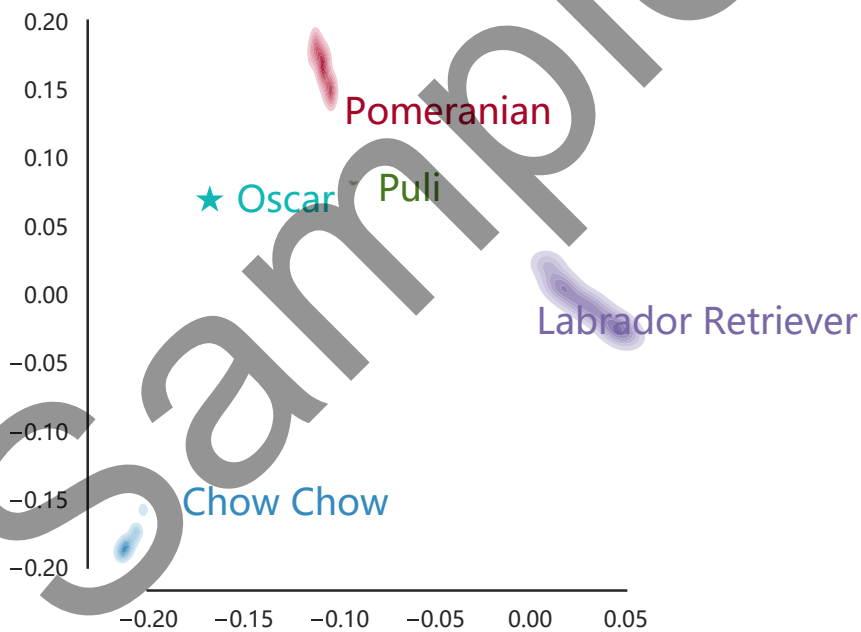
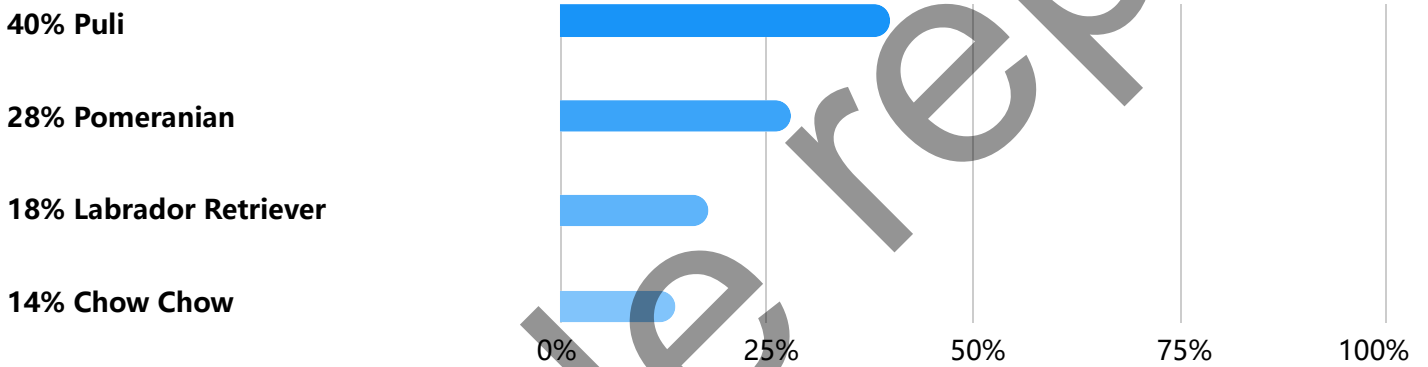


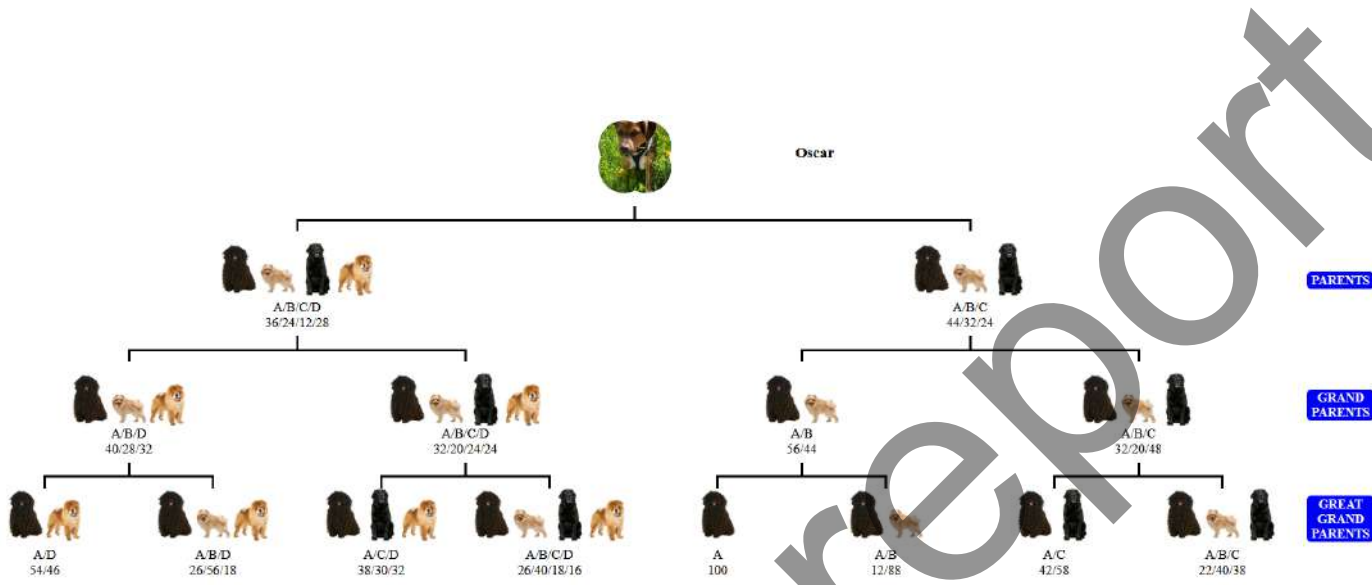


2.1 Breed

Breed Identification Report

Oscar is a mixed breed. The breed composition diagram is as follows:





Please note, the family tree above only shows the most likely scenario according to laws of genetics. It's just for reference.

Variety Description

Puli

Historical Origin

Originated in Hungary in the 10th century

Characteristics

Puli is a medium-sized ancient shepherd dog from Hungary. It is famous for its long rope-like coat. It is used for herding and guarding domestic animals. It is said that it came from more than 1,000 years ago. It migrated from Central Asia and was introduced by the Magyars. It can fight wolves. Its thick coat prevents wolves or bears from being bitten. Nomads cherish them.

Anecdote

In Asia, the Polly dog breed can be traced back to 2000 years ago. In ancient times, the Polly dog was very popular for herding. Around the beginning of the 20th century, traditional animal husbandry was replaced by intensive agriculture, so This kind of dog has become a domestic dog, but it is not very popular.

Common Genetic Diseases

Hip dysplasia, Progressive Retinal Atrophy

Traits

Average Life Expectancy:12–16 years

Average Height:Female: 36–42 cm, Male: 39–45 cm

Average Weight:Female: 10–13 kg, Male: 13–15 kg



Variety Description

Pomeranian

Historical Origin

It originated in Germany in ancient times

Characteristics

The Pomeranian is named after the German Pomeranian and Central European Pomeranian regions. Because of its small size, it is classified as a toy dog. They are usually friendly and lively, but there are When other dogs are together, they will actively prove themselves. The dog breed is very vigilant and will bark fiercely when it realizes that their environment has changed.

Anecdote

The first member of the Pomeranian was successfully registered with the American Kennel Club in 1898 and was recognized in 1900. In 1912, two Pomeranians became one of the silent survivors of the Titanic. Now the Dogs have become one of the most popular dog breeds in the world.

Common Genetic Diseases

Hereditary Vitamin D-Resistant Rickets, Hyperuricosuria, Progressive Retinal Atrophy, Congenital hypothyroidism, Dilated Cardiomyopathy, Glycogen Storage Disease

Traits

Average Life Expectancy:12 – 16 years

Average Height:18-30 cm

Average Weight:1.4-3.2 kg



Variety Description

Labrador Retriever

Historical Origin

It originated in Newfoundland before 1800 AD

Characteristics

The Labrador Retriever is a shotgun dog, one of the most popular dog breeds in the United States, Britain and Canada. They are often trained to help the blind and autistic patients as treatment dogs, It also completes screening and testing for law enforcement agencies and other official agencies. In addition, they are also sporting dogs and hunting dogs.

Anecdote

In 1903, the Kennel Club recognized the Labrador Retriever; in 1917, people registered the first Labrador Retriever in the American Kennel Club. It appeared on December 12, 1928. The first dog on the cover of "Life" magazine is the black Labrador retriever named "Blind Arden".

Common Genetic Diseases

Alexander disease, Centronuclear Myopathy, Congenital Myasthenic Syndrome, Canine elliptocytosis, Hyperuricosuria, Narcolepsy, Dwarfism, X-linked Myotubular Myopathy, Progressive Retinal Atrophy, Von Willebrand Disease Type I, Pyruvate kinase deficiency, Degenerative myelopathy, Hereditary Nasal Parakeratosis, Exercise Induced Collapse, Developmental dysplasia of the hip (DDH)

Traits

Average Life Expectancy:10–12 years (Adult)

Average Height:Male: 57–62 cm, Female: 55–60 cm

Average Weight:Male: 29–36 kg, Female: 25–32 kg



Variety Description

Chow Chow

Historical Origin

It originated in Tibet in ancient times

Characteristics

Chow Chow is native to northern China and is also known as the Tang dog, which is the 'dog of the Tang Empire'. They guard the temple and are one of the few ancient dog breeds that still exist in the world today. 1. Later Chow Chow was also used for herding, hunting and guarding.

Anecdote

A Chinese legend mentions a large war dog from Central Asia. Just like the black lion, it refers to the Chow Chow. It is said that a Chinese ruler once owned as many as 5,000 Chow Chow. Marco Polo once left a record: The Chinese used this dog to pull a sled. There is also a saying that the original teddy bear was created based on Queen Victoria' s Chow Chow.

Common Genetic Diseases

Canine elliptocytosis, Hereditary cataract, Primary Open Angle Glaucoma, Developmental dysplasia of the hip (DDH)

Traits

Average Life Expectancy:9–15 years

Average Height:Male: 48–56 cm, Female: 46–51 cm

Average Weight:Male: 25–32 kg, Female: 20–27 kg



Sample report



2.2 Genetic diseases

Single-gene disease detection report

No snp mutation found in 133 canine single diseases.

Sample report





2.2 Genetic diseases

Complex disease detection report

Congenital sensorineural deafness is due to the degeneration of cochlear cells or cochlear nerve cells. The function of the cells as receptors disappears, leading to loss of sensorineural hearing. The development of bony labyrinth, membranous utricles and semicircular canals is complete. Striate blood vessels that supply the cochlea are degenerated at first, and then the hair cells of the organ of corti develop from the base to the top of the cochlea. The hair cells are non-renewable and eventually cause deafness.

The affected side has complete hearing loss, no response to surrounding sounds, easy to startle, and difficulty in locating the sound source.

According to the history of the disease and the family's prevalence, a hearing test should be performed. If result of the otoscope examination are normal, a brainstem auditory response test is required. The disease is irreversible and there is currently no effective treatment. Pay attention to identify and treat external and middle ear diseases.

Items	Congenital sensorineural deafness
Test results	High risk
Relative risk	89.99
Gene	FUBP1; NELL2; CRIM1; FRMD8; HNF4G near
Genotype	A,A; C,C; A,A; C,C; C,T

The relative risk of Congenital sensorineural deafness in this sample is higher than 89.99% of dogs.





2.2 Genetic diseases

Complex disease detection report

Obsessive-compulsive disorder refers to recurring behaviors that occur beyond the normal range or beyond the frequency or interval required to achieve its apparent purpose, such as sports behaviors, grooming behaviors, feeding behaviors, and hallucinations. Many of the behaviors are unique to pets, but they are exaggerated and lasted for a long time, hindering the normal function of pets in their social environment. It is generally believed that obsessive-compulsive disorder is caused by abnormal neuropharmacological activities in brain.

Items	Obsessive-compulsive disorder
Test results	High risk
Relative risk	87.76
Gene	DSC3; CPQ
Genotype	G,G; C,C

The relative risk of Obsessive-compulsive disorder in this sample is higher than 87.76% of dogs.

Some manifested as uninterrupted licking of hair, even causing skin damage and hair loss. Or spending a lot of time swallowing, chewing or sucking various items such as cloth, leather and plastic. At the same time, pets will complain call, hide or move to get out of this state. Some animals will have hallucinations, screaming, chasing or looking directly at imaginary objects.

It is necessary to understand the medical history, observe the clinical symptoms, carefully record the behavioral symptoms and their duration. Try to find out the factors that induce these behaviors and try to avoid them. In some special conditions, it may be similar to epileptic seizures. Some behaviors may be very complicated, and a comprehensive physical examination should be carried out at the same time to eliminate and treat related diseases, and investigate the role of the disease in the performance behavior. Generally, medical treatment can be considered include Ami Triptiline, Buspirone, Clomiphene, Hydrocodone and Fluoxetine. But there may be side effects such as drowsiness, vomiting, diarrhea and arrhythmia.





2.2 Genetic diseases

Complex disease detection report

Congenital megaesophagus is caused by the hypoplasia of esophageal nerve distribution, which shows as abnormal esophageal motility, causing esophageal dilation and food or fluid intake disorders, stopping in the esophagus. The esophagus becomes completely paralyzed as overall expansion changes, and some of them show improvement in function as the esophagus matures with age.

Items	Congenital megaesophagus
Test results	Medium risk
Relative risk	65.64
Gene	FBXL14 near
Genotype	G,G

The relative risk of **Congenital megaesophagus** in this sample is higher than 65.64% of dogs.

The onset varies from lactation to adulthood, appears as reflux of food and water through the mouth and nose, difficulty in swallowing, large amount of saliva, oral cavity due to fermentation of inhaled substances. Dog has slow growth and weight loss. Dyspnea, cough, and shortness of breath show due to food entering lungs.

Pull up hind limbs of the dog, and feel the swelling of the esophagus from side of neck. X-rays can confirm residual food, fluid or air in the esophagus. Symptoms of aspiration pneumonia such as blurred lung alveoli also appear. This disease can be confirmed by esophageal X-ray imaging, the contrast agent stays in the lumen. Note that, vets need to pay attention to other acquired diseases of esophageal hypofunction such as hypothyroidism, adrenal hypofunction, esophageal inflammation, heavy metal poisoning and autoimmune diseases, etc. Severe symptoms can be fed via a gastric catheter. When foreign body pneumonia occurs, antibiotics could be used. The effect of surgical treatment is not clear. Early treatment has significant effects, and some animals' posterior esophagus could automatically enhanced as they become mature.





2.2 Genetic diseases

Complex disease detection report

Mast cell tumor(MCT) is a tumor formed by the accumulation of mast cells originating in the dermis and subcutaneous tissue. It is a round cell tumor. It is classified as malignant tumor in histology and is the most common skin tumor in dogs. Mast cells are The cells that exist in the normal body contain heparin, histamine and a series of vasoactive substances, which are involved in normal inflammatory and allergic reactions. According to histological standards, mast cell tumors are divided into three categories: undifferentiated, Moderately differentiated, well-differentiated, and well-differentiated mast cell tumors have a low metastasis rate (less than 10%).

Usually appear in the perineum, trunk, hind limbs and external genitalia. It is manifested as a single lesion, or multiple lesions, and skin or subcutaneous edema, papules, nodules, etc. may appear. The diameter ranges from several millimeters to several centimeters. Varying, blurred or clear boundaries, soft or hard tissues, with or without hair growth on the surface, accompanied by ulcers, redness, and pigmentation with or without. Some have gastric or duodenal ulcers and coagulation disorders, showing the stomach Intestinal ulcers, vomiting (possibly with blood), delayed wound healing, hypotensive shock, anorexia, melena and abdominal pain, etc.

Diagnosis is based on clinical symptoms and the results of skin histocytology and pathology. Cytology shows many round nuclei and basophilic cytoplasmic granules, possibly eosinophils, and round cells in histopathology. There is no cystic infiltration layer or compact compression cord. At the same time, the animal's body should be checked for metastasis through imaging and blood test to assess the animal's physical condition. The treatment can be performed by surgical removal of tumor tissue.

Items	Mast cell tumor(MCT)
Test results	Medium risk
Relative risk	64.32
Gene	AP1M1 near
Genotype	G,G

The relative risk of Mast cell tumor(MCT) in this sample is higher than 64.32% of dogs.





2.2 Genetic diseases

Complex disease detection report

Hemangiosarcoma is a malignant hyperplastic tumor of vascular endothelial cells. Skin may be the primary or metastatic site.

Items	Hemangiosarcoma
Test results	Low risk
Relative risk	31.1
Gene	STX8
Genotype	C,T

The relative risk of Hemangiosarcoma in this sample is higher than 31.1% of dogs.

Lumps appear on the skin or under the skin of dogs, with light blue to red spots or nodules, usually less than 4 cm in diameter. It could also show subcutaneous spongy dark red to blue masses with unclear boundaries, greater than 10 cm in diameter. Symptoma usually accompanied by hair loss, bleeding or ulcers. It mostly occurs in the limbs and trunk of dogs. There may be abnormal bleeding such as thrombocytopenia and diffuse intravascular coagulation.

Diagnosis is based on clinical symptoms, which requires cytological examination and histopathological examination. In most cases of cytological examination, blood contains tumor endothelial cells, which are normal or large, with polymorphic cells and basophilic cytoplasm. There are obvious nucleoli. Histopathology shows skin or subcutaneous infiltrating atypical polymorphous densely stained spindle cell masses, which are easy to form vascular grooves and have different mitotic speeds. At the same time, relevant blood tests and imaging examinations should be performed to assess the body's condition and tumor metastasis. Surgery is the main treatment method.





2.2 Genetic diseases

Complex disease detection report

Lymphoma, also called lymphosarcoma, is a malignant tumor of the lymphatic system. It is a common tumor disease in dogs, accounting for 7% to 24% of canine tumor diseases. Lymphoid tumors may be caused due to genetics factors, carcinogens, immune factors, or retroviral pathogen, which mainly affect lymph nodes and other organs such as liver or spleen. According to the anatomical location, they are divided into multicentric lymphoma, digestive tract lymphoma, mediastinal lymphoma and extranodal lymphoma. According to histological grading standard, it is divided into low, medium and high levels. According to the immunophenotypic characteristics of lymphocytes, it is divided into T-cell lymphoma and B-cell lymphoma. According to clinical manifestations, it is divided into lymphoma 1-5 Period.

Items	Lymphoma
Test results	Low risk
Relative risk	30.92
Gene	MCC
Genotype	G,G

The relative risk of Lymphoma in this sample is higher than 30.92% of dogs.

Lymphoma mainly affects middle-aged to elderly dogs. It mainly manifests as painless and progressive lymphadenopathy, which can be single or multiple, and any part outside the lymph nodes, such as spleen and gastrointestinal tract, may also be the first site of lymphoma. Multicentric lymphosarcoma manifests systemic lymphohistiosarcoma, loss of appetite, weakness, lethargy, weight loss, etc. Tropic lymphosarcoma showing weight loss, lethargy, vomiting, diarrhea, with or without bleeding. Skin type lymphosarcoma shows one or more skin lesions, starting with eczema and itching scars, and then becoming tumors. Transitional lymphosarcoma mainly manifests respiratory symptoms, and edema of the face and forelimbs caused by tumor compression and invading venous tubes.

Detailed systemic examination, palpating all lymph nodes throughout the body. Hematological examination to determine the condition of platelets, lymphocytes, eosinophils, and anemia. Biochemical examination to determine whether it is caused by hypercalcemia and nephropathy. X Light can detect enlargement of the sternum, lower lumbar lymph nodes, spleen and liver.





2.2 Genetic diseases

Complex disease detection report

Portosystemic vascular anomaly(PSVA) is an abnormality of blood vessels between the portal circulation and the systemic circulation. In large dogs, intrahepatic short circuits are common. Patent venous catheters are a common type of intrahepatic vascular short circuits. Short-circuits of extrahepatic blood vessels are common in small dogs, portal vein simplification, portal vein-abdominal vena short-circuit, left gastric vein and abdominal vena short-circuit, and portal vein atresia. The short-circuited blood vessels make portal vein blood flow directly into the systemic circulation, and the liver cannot remove potential toxins from the blood, resulting in Hepatic encephalopathy and lack of hepatic nutrients in portal vein blood at the same time cause liver atrophy.

Commonly seen in animals under 3 years of age, manifested as developmental delay, mental decline, convulsions, coma or blindness. Salivation, loss of appetite, vomiting, diarrhea, polydipsia, polyuria, hematuria, elevated body temperature, etc.

Diagnosed through hematology, biochemistry, imaging, urinalysis and liver biopsy. Anemia is seen, urine specific gravity is usually less than 1.030, ammonium urate crystals are seen, and the kidney volume is about 70% larger than normal. Low serum creatinine And urea nitrogen, low albumin, low cholesterol, moderately elevated AST, ALT, ALKP, GGT. The bile acid concentration is higher than normal regardless of fasting and postprandial. The diagnosis requires rectal imaging examination and laparotomy. Contrast B-ultrasound shows small, reduced and irregular blood vessels in the liver. Pay attention to the differentiation from liver failure, congenital urea cycle enzyme deficiency, epilepsy, intrahepatic arteriovenous fistulas, etc.

Items	Portosystemic vascular anomaly(PSVA)
Test results	Low risk
Relative risk	28.21
Gene	None
Genotype	A,A

The relative risk of Portosystemic vascular anomaly(PSVA) in this sample is higher than 28.21% of dogs.





2.2 Genetic diseases

Complex disease detection report

Hypothyroidism is due to the lack of thyroxine T4 and 3,5,3,-triiodothyronine T3, leading to clinical symptoms involving almost all organ systems.

Items	Hypothyroidism
Test results	Low risk
Relative risk	26.58
Gene	ZNF76
Genotype	C,A

The relative risk of Hypothyroidism in this sample is higher than 26.58% of dogs.

Mental disorders and abnormal skeletal development, leading to disproportionate dwarfism, goiter may also be present. Skin pigmentation, keratinization and seborrhea, dry coat, shedding or pyoderma due to decreased immunity The tongue and eyeballs of the affected dog are protruding, resulting in abnormal appearance. Lethargy, lethargy, loss of appetite, constipation and cramps, ataxia.

Thyroid function tests can be performed to confirm hypothyroidism. At the same time, CBC, serum biochemistry, thyroid biopsy, histopathology and ultrasound can be performed. It can show mild non-regenerative anemia, high cholesterol, and high creatine. Kinase, high alkaline phosphatase, low sodium, hypoglycemia, etc. The cardiovascular system can show that the heart rate, blood pressure, stroke volume, contractility, and anterior ejection period decrease, and the thickness of the left ventricle posterior wall and ventricular septum decrease. Appears Relevant complications should be treated with symptomatic treatment and thyroid hormone therapy should be performed at the same time.





2.2 Genetic diseases

Complex disease detection report

Hip dysplasia is an abnormality in the hip fossa, due to inconsistencies between muscles and overgrown bones, hip instability leads to subluxation of the acetabular and femoral head, and the hip joint cannot remain stable. Daily body activities such as standing, walking, weight bearing and other sports will produce hip wear, with the increase of damage accumulation over time, the hip joint will appear morphological structural changes such as femoral neck thickening, osteophytes and acetabular sclerosis, secondary osteoarthritis and pain. Severe cases can lead to claudication and painful arthritis. In many dog breeds, especially large dog breeds, hip dysplasia is the single most common cause of hip arthritis.

Items	Hip dysplasia
Test results	Low risk
Relative risk	9.16
Gene	none; SRBD1; RPN1 near; KIF26B
Genotype	G,G; C,C; C,T; T,C

The relative risk of Hip dysplasia in this sample is higher than 9.16% of dogs.

Hip dysplasia usually occurs at 18 months and can range from mild mobility problems to severe paralysis and osteoarthritis. Sick dogs usually reduce hip movement, which leads to a 'rabbit jump', which means that the two hind legs move together, which can also lead to muscle stiffness. Because the hip joint cannot move freely, the affected dog usually adjusts the spine to adapt to the changes in the hip joint, which can cause spine, knee joint or soft tissue problems. Hip joint pain usually occurs after activities, and it will be significantly reduced or disappeared after rest.

Diagnosis is based on clinical symptoms and X-ray examination. Other environmental factors that may cause illness include excess weight, minor injuries, hip joints overworked or worn, torn ligaments, and repetitive joint movements. There is no way to completely cure the disease, but there are ways to reduce clinical symptoms. Non-surgical treatment options include three elements: weight control, exercise control and drug therapy. Among them, weight control is very important, and sometimes simply reducing weight alone can control all symptoms of diarrhea. Proper exercise stimulates the growth of cartilage, but excessive exercise may cause damage to the cartilage.





2.2 Genetic diseases

Complex disease detection report

Osteosarcoma is a primary bone tumor in dogs. It is caused by mesenchymal stem cells in the bones. It originates deep inside the bones. When it grows outwards, the bones are destroyed from the inside and cause strong pain. Osteosarcoma is mainly caused by accumulation or exposure to carcinogens or genetic factors. It accounts for up to 85% of all bone malignant tumors. It mainly affects middle-aged to elderly dogs, especially large dog breeds such as Great Danes and Irish wolfhound. However, it can also appear in any other bone structure. The limbs account for 75%-85% of all cases. Other bones that can be affected include the upper jaw, mandible, spine, skull, ribs, and nasal cavity, paranasal sinuses and pelvis. Osteosarcoma of the external bone is relatively rare, but it can be found in breast tissue, subcutaneous tissue, spleen, intestine, liver, kidney, testis, vagina, eyes, stomach, ligament, synovium, meninges and adrenal glands.

Long bone pain and lumps (lumps not related to body surface trauma or scars), nodules under the skin, claudication, and weakness. Sudden fractures and frequent fractures and rupture of the periosteum during general physical activity. The intense pain caused irritability, aggressiveness, loss of appetite, weight loss, whimpering, insomnia, and reluctance to exercise.

The disease is most common in the leg bones of large dogs. It usually manifests as limb pain or fractures during low-intensity activities in dogs. If the tumor is large enough, the leg can be seen to be significantly swollen, but it is usually. It is believed that cancer cells have spread. The diagnosis is mainly based on clinical examination, X-ray and histological examination. X-ray shows osteolysis, bone hyperplasia, periosteal reaction, soft tissue swelling, pathological fracture and metastatic lung injury. Related blood tests and MRI examinations Determine body function and tumor metastasis. Bone biopsy is required for pathological diagnosis to confirm the diagnosis. Pay attention to osteomyelitis, trauma, bone infarction and benign cystic lesions. Treatment mainly adopts amputation combined with chemotherapy and immunotherapy.

Items	Osteosarcoma
Test results	Low risk
Relative risk	8.98
Gene	FBL near; KIAA1462
Genotype	G,T; A,C

The relative risk of Osteosarcoma in this sample is higher than 8.98% of dogs.





2.3 Hair trait

Hair trait report

The coat color most likely to be carried by this sample is Gray wolf pattern coat; The hair type most likely to be carried by this sample is short curly hair.

The coat color of dogs is determined by the interaction of multiple genetic loci, and completely opposite results may be obtained between different loci. Therefore, the test is only for reference, please refer to the actual appearance.

Associated genes	Result
B (brown) locus	BB
B (brown) locus	BB
B (brown) locus	BB
E (extension) locus	EE
K (dominant black) locus	K ^y K ^y
A (agouti) locus	a ^w a ^w ,a ^w a ^l ,a ^w a
A (agouti) locus	a ^w a ^w ,a ^w a ^l ,a ^w a
A (agouti) locus	a ^w a ^w ,a ^w a ^l ,a ^w a
A (agouti) locus	a ^w a ^w ,a ^w a ^l ,a ^w a
D (dilute) locus	Dd

*BB refers to black;

*EE refers to normal extension, means pattern expressed as per alleles present at A and K loci;

*K^yK^y refers to phaeomelanin permitted (pattern expressed as per alleles present at A and E loci);

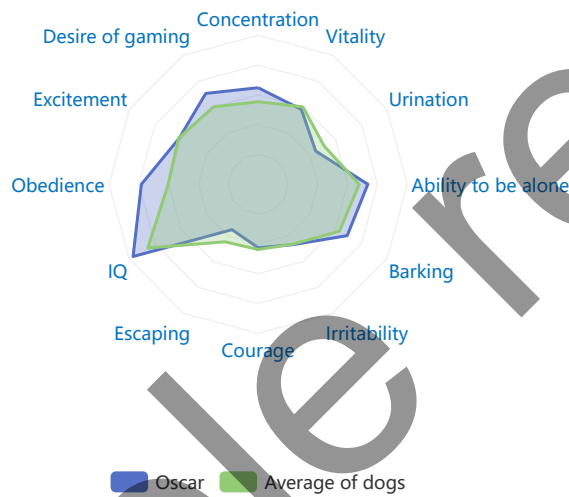
*a^wa^w,a^wa^l,a^wa refers to wild-type agouti. Each hair with 3-6 bands alternating black and tan. Also called wolf sable;

*Dd refers to not diluted color.



2.4 Behaviours

Behaviours determination



Concentration refers to the degree to which a dog's concentration is affected by external stimuli, such as being attracted by a leaf on the asphalt road, a long one of many intermittent and short sounds, being attracted by a plastic bag blown by the wind, or chasing a fly. Birds and other small animals that have passed by, the lower the score, the more the surface is affected by external stimuli, and the lower the concentration.

Desire of gaming refers to the activity of the dog, the desire to play games, the higher the score, the more active, the more energetic, and the stronger the desire to play.



Excitement refers to the dog's response after being stimulated. The higher the score, the stronger the response to stimulation or excitement, such as walking, driving, doorbell ringing, guests visiting, the owner returning home after a period of time, and the dog's excitement.

Obedience refers to dog's willingness to obey orders. Dogs with high scores show more concern for their owners, willingness to obey orders, positive reactions, quick learning, and high obedience.

IQ refers to the dog's IQ index, the higher the score, the smarter it is.

Escaping refers to the probability that the dog will run away, or escape home or owner at the first opportunity. The higher the score, the greater the probability.

Courage refers to the dog's fear and anxiety about unfamiliar things. The higher the score, the easier it is to have fear or anxiety.

Irritability refers to the dog's aggression. The higher the score, the easier it is to produce aggressive behavior, which has nothing to do with combat effectiveness.

Barking refers to the degree of continuous barking of the dog. The higher the score, the more severe the continuous barking when the dog is excited or stimulated.

Ability to be alone refers to the dog's perception of loneliness and whether it is prone to separation anxiety. The higher the score, the stronger the perception of loneliness and the lower the ability to be alone.

Urination refers to the disorder of urination when the dog is at home alone. The higher the score, the greater the possibility of disorderly urination.

Vitality refers to the activity of the dog, the higher the score, the more lively, energetic, and the more interesting and noisy personality, the greater the amount of exercise required.





3 References

Single-gene genetic diseases:

2-8-Dihydroxyadenine
Alexander disease
Alport Syndrome
Autosomal Recessive Amelogenesis Imperfecta
Axonal Disease Fetal-onset neonatal neuroaxonal
Axonal Disease Hypomyelination and Tremor
Axonal Disease Shaking Puppy Syndrome
C3 deficiency
Canine elliptocytosis
Canine Multifocal Retinopathy - Type 1
Canine Multifocal Retinopathy - Type 2
Canine Multifocal Retinopathy - Type 3
Catalase Deficiency
Centronuclear Myopathy
Cerebellar abiotrophy
Cerebellar Ataxia
Cerebellar disease Cerebellar ataxia
Cerebellar disease Cerebellar hypoplasia
Chondrodysplasia
Cleft lip with or without cleft palate
Coagulopathy Thrombopathia
Collie eye anomaly
Congenital hypothyroidism
Congenital Macrothrombocytopenia
Congenital Myasthenic Syndrome
Congenital Myotonia
Congenital Stationary Night Blindness
Cyclic neutropenia
Cystinuria
Cystinuria Type II-A
Cystinuria Type II-B
Cystinuria 1
Cystinuria 2
Cystinuria 4
Day blindness
Degenerative Myelopathy
Dermatofibrosis
Dilated Cardiomyopathy
Dry eye curly coat syndrome
Dwarfism
Dystrophic epidermolysis bullosa
Early retinal degeneration
Ectodermal dysplasia
Encephalopathy
Episodic falling syndrome
Exercise Induced Collapse
Factor VII deficiency
Familial Nephropathy
Fetal-onset neuroaxonal dystrophy
Fucosidosis
Gallbladder mucocele formation
Gangliosidosis 1
Gangliosidosis GM2 Gangliosidosis
Glanzmanns thrombasthenia Type I
Globoid cell leukodystrophy
Glycogen Storage Disease Type Ia
Glycogen Storage Disease Type II
Glycogen Storage Disease Type IIIa
Hemophilia A
Hemophilia B
Hereditary Cataract
Hereditary Footpad Hyperkeratosis
Hereditary Nasal Parakeratosis
Hereditary Vitamin D-Resistant Rickets
Hyperuricosuria
Ichthyosis
Imerslund-Grasbeck Syndrome
Intestinal malabsorption of cobalamin
Juvenile Epilepsy
L-2-HGA-L-2-hydroxyglutaric aciduria
Late Onset Ataxia
Ligneous Membranitis

**X: Carrier




Long QT Syndrome
 Lysosomal Storage Disease
 Malignant Hyperthermia
 May-Hegglin anomaly
 MPS VI
 Mucopolysaccharidosis Type IIIA
 Mucopolysaccharidosis Type VII
 Multi-Drug Sensitivity
 Muscular dystrophy
 Musladin-Lueke Syndrome
 Myostatin defect
 Myotubular Myopathy 1
 Narcolepsy
 Neonatal ataxia
 Neonatal Encephalopathy with Seizures
 Neuroaxonal Dystrophy
 Neuronal Ceroid Lipofuscinosis
 Neuronal Ceroid Lipofuscinosis 1
 Neuronal Ceroid Lipofuscinosis 10
 Neuronal Ceroid Lipofuscinosis 12
 Neuronal Ceroid Lipofuscinosis 2
 Neuronal Ceroid Lipofuscinosis 5
 Neuronal Ceroid Lipofuscinosis 6
 Neuronal Ceroid Lipofuscinosis 8
 Oculoskeletal Dysplasia 1
 Osteogenesis imperfecta
 Pachyonychia congenita
 Persistent Mullerian Duct Syndrome
 Phosphofructokinase deficiency
 Platelet Adhesion Defect
 Polyneuropathy
 Prekallikrein Deficiency
 Primary ciliary dyskinesia
 Primary hyperoxaluria type I
 Primary Lens Luxation
 Primary Open Angle Glaucoma
 Progressive neuronal abiotrophy
 Progressive Retinal Atrophy
 Progressive Retinal Atrophy - cord1
 Progressive Retinal Atrophy - cord2
 Progressive retinal atrophy - Dominant
 Progressive Retinal Atrophy - PRA1
 Progressive Retinal Atrophy - PRCD
 Progressive Retinal Atrophy - RCD1
 Progressive Retinal Atrophy - RCD3
 Progressive Retinal Atrophy - rcd4
 Progressive Retinal Atrophy - Type A
 Protein Losing Nephropathy
 Pyruvate Dehydrogenase Phosphatase Deficiency
 Pyruvate kinase deficiency
 Renal Cystadenocarcinoma and Nodular
 Sensory ataxic neuropathy
 Severe Combined Immunodeficiency
 Spinocerebellar Ataxia
 Spondylocostal Dysostosis
 Spongiform leukoencephalomyelopathy
 Trapped Neutrophil Syndrome
 Von Willebrand Disease Type I
 Von Willebrand Disease Type II
 Von Willebrand Disease Type III
 X-linked Severe Combined Immunodeficiency

Complex genetic diseases:

- Adult dog deafness
- Amylase
- B-cell lymphoma
- ✗ Congenital megaesophagus
- ✗ Congenital sensorineural deafness
- Duchenne muscular dystrophy
- ED
- ✗ Hemangiosarcoma
- ✗ Hip dysplasia
- ✗ Hypothyroidism
- ✗ Lymphoma
- ✗ Mast cell tumor(MCT)
- ✗ Obsessive-compulsive disorder
- ✗ Osteosarcoma
- ✗ Portosystemic vascular anomaly(PSVA)
- Rupture of the cranial cruciate ligament

**✗ : Carrier



Breed list:

Abruzzo Mastiff
Afghan Hound
Airedale Terrier
Akita
Alaskan Malamute
American Cocker Spaniel
American Eskimo Dog
American hairless Terrier
American Pit Bull Terrier
American Staffordshire Terrier
Anatolian Shepherd
Australia Terrier
Australian Cattle Dog
Australian Kelpie
Australian Shepherd
Australian Silky Terrier
Azawakh
Basinji
Basset Hound
Beagle
Bearded Collie
Belgian Malinois
Belgian Shepherd Dog
Bellington Terrier
Bernese Mountain Dog
Black Russia Terrier
Boerboel
Border Collie
Border Terrier
Borzoi
Boston Terrier
Bouvier des Flandres
Boxer
Bracco
Briard
Brittany
Bull Terrier
Bullmastiff

Cairn Terrier
Cane Corso
Canis aureus
Cardigan Welsh Corgi
Carolina Dog
Catehola Leopard Dog
Cavalier King Charles Spaniel
Chesapeake Bay Retriever
Chihuahua
Chinese Crested Dog
Chinese Shar-pei
Chinook
✓ Chow Chow
Cirneco dell'Etna
Coton de Tulear
Curl Bichon Frise
Curly Coated retriever
Czechoslovakian Wolfdog
Dachshund
Dalmatian
Doberman Pinscher
Dogue de Bordeaux
English Bulldog
English Cocker Spaniel
English Foxhound
English Setter
English Springer Spaniel
Eurasier
Field Spaniel
Finnish Spitz
Flat-coated Retriever
French Bulldog
German Shepherd Dog
German Shorthaired Pointer
German Wirehaired Pointer
Giant Schnauzer
Glen of Imaal Terrier
Golden Retriever

**✓ : Carrier



Goldendoodle
Gordon Setter
Great Dane
Great Swiss Mountain Dog
Greenland Dog
Greyhound
Griffon Bruxellois
Havanese
Ibiza Hound
Icelandic Sheepdog
Irish Setter
Irish Terrier
Irish Water Spaniel
Irish Wolfhound
Italian Greyhound
Jack Russell Terrier
Japanese Chin
Keeshond
Kelly Blue Terrier
Komondor
Kuvasz
✓ Labrador Retriever
Large Münsterländer
Leonberger
Lhasa Apso
Maltese
Mastiff
Miniature Bull Terrier
Miniature Dachshund
Miniature Pinscher
Miniature Poodle
Miniature Schnauzer
Molossar
Neapolitan Mastiff
New Guinea Singing Dog
Newfoundland
Norfolk Terrier
Norwegian Elkhound

Norwich Terrier
Nova Scotia Duck Hunting
Retriever
Old English Sheepdog
Otterhound
Palatore Dog
Papillon
Parson Russell Terrier
Pekingese
Pembroke Welsh Corgi
Peruvian Inca Orchid
Petit Basset Griffon Vendéen
Pharaoh Hound
Picardy Spaniel
✓ Pomeranian
Portuguese Water Dog
Poodle - Standard
Poodle - Toy
Pug Dog
✓ Puli
Pumi
Pyrenean Mountain Dog
Rat Terrier
Redbone Coonhound
Rhodesian Ridgeback
Rottweiler
Saarlooswolfdog
Saluki
Samoyed
Schipperke
Collie
Scotland Terrier
Scottish Deerhound
Shetland Sheepdog
Shiba Inu
Shih Tzu
Siberian Husky
Sloughi
Soft-coated Wheaten Terrier

Saint Bernard
St.huberhound
Staffordshire Bull Terrier
Standard Schnauzer
Sussex Spaniel
Sweden Wa Hande dogs
Tervuren
Tibet Terrier
Tibetan Mastiff
Tibetan spaniel
Toy Fox Terrier
Toy Manchester Terrier
Vizsla
Volpino
Weimaraner
West Highland White Terrier
Whibit
Wire Hair Fox Terrier
Wirehaired Pointing Griffon
Wolf
Xigou
Xoloitzcuintle
Yorkshire Terrier

**✓ : Carrier





CANINE BREED COMPOSITION CERTIFICATE

Certified breed analysis and genetic makeup for

Oscar

BREED BREAKDOWN

Puli – 40%

Pomeranian – 28%

Labrador Retriever – 18%

Chow Chow – 14%

LAB SAMPLE ID – LHK220923002

CASE REF: Easy DNA[PETGEN74429UK]

28, October, 2022

